

The Laminated Nature of the Pectoralis Major Muscle and the Redefinition of the Inframammary Fold Clinical Implications in Aesthetic and Reconstructive Breast Surgery

Melvin M. Maclin II, MD^{a,*}, Olivier A. Deigni, MD, MPH^b,
Bradley P. Bengtson, MD^c

KEYWORDS

- Pectoralis major muscle • Inframammary fold • Subpectoral augmentation • Breast augmentation
- Breast reconstruction • Acellular dermal matrix • Breast inflection points • Chest wall anatomy

KEY POINTS

- The inframammary fold (IMF) is a critical landmark and aesthetic structure in breast surgery, yet it is poorly understood.
- The skin envelope is considered a separate entity from the chest wall; however, its surgical manipulation is not independent of chest wall anatomy.
- The pectoralis major muscle is a key structure in both cosmetic and reconstructive surgery, and its structure and performance are related to its inferior costal origins.
- A better understanding of the relationship of the IMF, pectoralis, and chest wall anatomy can offer improved outcomes in breast surgery.

INTRODUCTION

The breast is appreciated aesthetically and clinically for its shape, projection, and volume. Multiple techniques have evolved over the years to modify, enhance, or recreate the breast mound. To this end surgical techniques have evolved to manipulate the breast skin envelope, soft tissues, and chest wall anatomy, with and without prosthetic devices. The pectoralis major specifically is altered for pocket dissection and implant coverage. Both the aesthetic and reconstructive surgeons are

intimately aware of its relationship to the chest wall and the breast soft tissues. Both are able to achieve outstanding outcomes; however, the authors present an alternative appreciation of the pectoralis and its relationship to the breast. The authors liken the comparison to the tale retold by John Saxe of the 6 blind wise men and the elephant (**Fig. 1**). Although Saxe claims the learned men were wrong, the authors propose to illustrate a broader perspective on the nature of the pectoralis.

^a Parkcrest Plastic Surgery, 845 North New Ballas Court, Suite 300, St Louis, MO 63141, USA; ^b St Louis University, St Louis, MO, USA; ^c Bengtson Center for Aesthetics & Plastic Surgery, Michigan State University, East Lansing, MI, USA

* Corresponding author.

E-mail address: drmaclin@earthlink.net

The Blind Men and the Elephant, John Godfrey Saxe (1816–87)

*It was six men of Indostan
To learning much inclined,
Who went to see the Elephant
(Though all of them were blind),
That each by observation
Might satisfy his mind.*

*The First approached the Elephant,
And happening to fall
Against his broad and sturdy side,
At once began to bawl:
“God bless me! but the Elephant
Is very like a WALL!”*

*The Second, feeling of the tusk,
Cried, “Ho, what have we here,
So very round and smooth and sharp?
To me 'tis mighty clear
This wonder of an Elephant
Is very like a SPEAR!”*

*The Third approached the animal,
And happening to take
The squirming trunk within his hands,
Thus boldly up and spake:
“I see,” quoth he, “the Elephant
Is very like a SNAKE!”*

*The Fourth reached out an eager hand,
And felt about the knee
“What most this wondrous beast is like
Is mighty plain,” quoth he:
“'Tis clear enough the Elephant
Is very like a TREE!”*

*The Fifth, who chanced to touch the ear,
Said: “E'en the blindest man
Can tell what this resembles most;
Deny the fact who can,
This marvel of an Elephant
Is very like a FAN!”*

*The Sixth no sooner had begun
About the beast to grope,
Than seizing on the swinging tail
That fell within his scope,
“I see,” quoth he, “the Elephant Is very like
a ROPE!”*

*And so these men of Indostan
Disputed loud and long,
Each in his own opinion
Exceeding stiff and strong,
Though each was partly in the right,
And all were in the wrong!*



Fig. 1. The blind men and the elephant. (From Holton MA, Curry CM. Holton-Curry readers, volume 4. Chicago: Rand McNally & Company; 1914.)

REVIEW OF THE LITERATURE

The IMF is a critical visual marker for the breast, and its importance in both aesthetic and breast reconstruction surgery is the foundation of achieving acceptable results as emphasized by Carlson, the first of the wise men describing the IMF as an aesthetic structure.¹ Yet its structure and definition have been difficult to understand.^{2,3} To compound this, the relationship of the IMF with chest wall anatomy is only casually understood. A broader appreciation of the IMF as it relates to the skin, muscle, and chest wall aids in obtaining improved outcomes. Observations from clinical and cadaveric dissection are described to broaden this appreciation.

In a cadaveric study by Maillard and Garey,⁴ the IMF was approached from a subglandular approach with the breast soft tissues bluntly dissected off the chest wall until resistance was encountered. A crescent-shaped ligamentous band was identified stretching between the superficial surface of the pectoralis major muscle and the overlying skin. Bayati and Seckel⁵ later identified the IMF as a ligamentous structure arising from the periosteum of the fifth rib medially and extending to the interspace between the fifth and sixth ribs laterally. The ligament inserts onto the deep dermis in the region of the inframammary skin fold. In this study, the IMF was approached from a subpectoral approach with the pectoralis bluntly dissected off the chest wall. After avulsion of the insertions of the pectoralis muscle off the fifth rib, the ligament they identified at the inframammary crease resisted further blunt dissection

inferiorly. From this resistance the IMF serves a suspensory role. Further dissection beyond this area of resistance risks loss of support structure for an implant and with future bottoming out and double-bubble phenomenon. The second of the wise men describing the IMF as a physical support structure for the implant.

Whether the IMF exists as a ligamentous structure or a dense collagen network, the IMF functions as a zone of adherence between the dermis and the underlying pectoralis fascia.³ How this zone exists is poorly understood. In a study of 20 fresh cadavers, Matousek and Corlett⁶ identified a network of fascial condensations around the breast (Fig. 2). This fascial ring around the breast provides fixation between the deep muscle fascia and the anterior breast capsule. Inferiorly from the level of the fifth rib and inserting on the inferior pole of the breast they have named the triangular fascial condensation (Fig. 3). Furthermore, they identified short horizontal ligaments arising from the deep fascia of the rectus abdominis to Scarpa fascia and inserting into the inferior limit of the fold. Thus, the third wise man appreciating the IMF as part of the fascial framework of the breast.

The pectoralis and the IMF are considered separate structures that are related only by proximity. As mentioned previously, the relationship with the pectoralis muscle is only vaguely understood. A study by Nanigian and Wong⁷ examined the IMF as it relates to the inferior origin of the pectoralis major muscle. In a study of 20 female cadavers and 10 patients with planned mastectomy, the inframammary crease was marked transcutaneously with methylene blue and then approached internally along the superficial surface of the pectoralis muscle. The inferior origin of the pectoralis was identified visually, and the distance to the blue markings was measured. The average distance of the IMF below the visually identified inferior pectoralis origin was approximately 2 cm in both groups. The rib origin of the pectoralis was not identified, and the pectoralis muscle was not dissected from its inferior origin in this study. Madsen and Chim⁸ later evaluated the anatomic variance of the pectoralis muscle in the context of breast reconstruction. Fifty patients who underwent mastectomy were evaluated preoperatively and intraoperatively, and the relationship of the pectoralis origin with the IMF was assessed. The

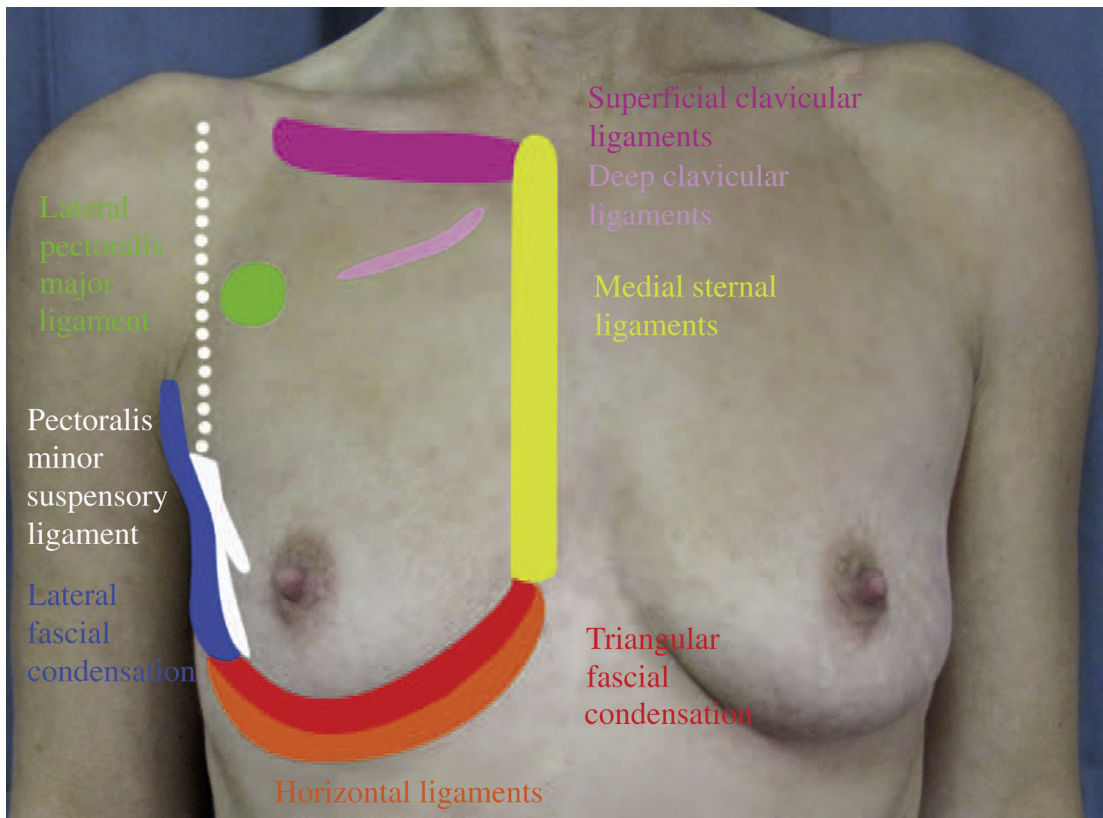


Fig. 2. The surface anatomic landmarks created by the ring of fascial attachments of the breast.

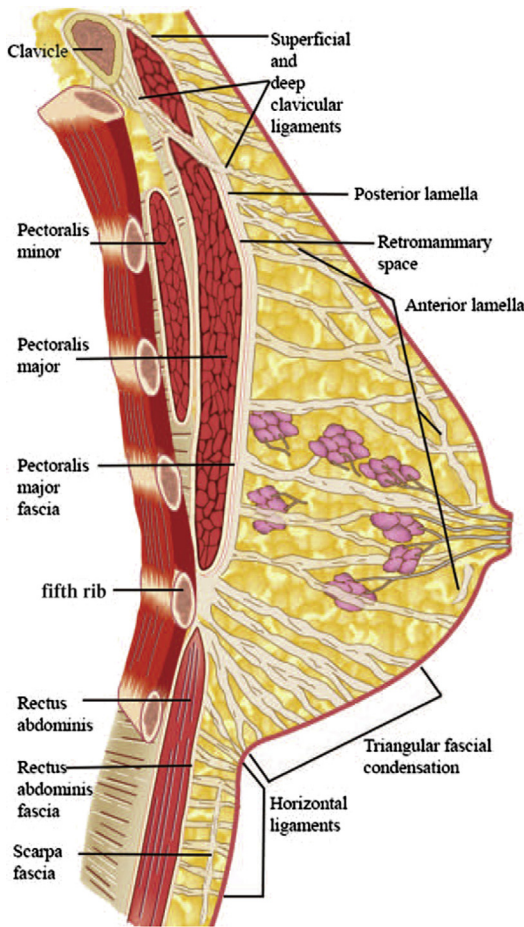


Fig. 3. Diagram of a sagittal section through the nipple, demonstrating the anterior and posterior breast capsule, ligaments, and triangular fascial condensation.

lowest inferior origin of the pectoralis was found at the fifth rib in 12%, sixth rib in 68%, and seventh rib in 20%. The IMF was noted to rest 1 rib level below the pectoralis in 36% of patients and at the same level in 61%. The implications for the anatomic location of the IMF to the pectoralis origin are of particular relevance for breast reconstructive surgery. Here, the fourth wise man who believes the 2 structures have no relationship other than proximity. The structures are considered to exist independently, yet with both breast augmentation and reconstruction the 2 structures have an intimate relationship.

LAMINATED NATURE OF PECTORALIS ***Crescent-Shaped Origin of Muscle***

The pectoralis muscle is a flat fan-shaped muscle on the anterior chest wall that acts to adduct and rotate the arm. The muscle has a crescentic origin

from the medial half of the clavicle, the manubrium and body of the sternum, the costal cartilages of the second to sixth ribs, and the aponeurosis of the external oblique muscle (**Fig. 4**). All fibers converge toward the axilla to merge and insert on the lip of the bicipital groove of the humerus. The medial and inferior origins have the most clinical significance to the breast surgeon.⁹

The muscle is elevated and separated from the pectoralis minor for both augmentation and breast reconstruction to allow submuscular placement of the implant. With dual-plane augmentation and breast reconstruction the inferior origin of the pectoralis is divided.^{10,11} Much controversy exists regarding the extent and degree of inferior and medial division. Underdissection can result in undesirable shape and projection.¹² Overdissection can result in symmastia, window shading, and implant malposition.¹³

Dual Layer of Pectoralis

The inferior border of the pectoralis is released off the chest wall to initiate breast reconstruction and with dual-plane augmentation. However, it is in the reconstructive arena where one is able to visualize the transected end of the muscle. In both partial submuscular and acellular dermis-based reconstructions, the free end of the muscle is sutured. After several years of manipulation, it was finally appreciated that the free edge represented only a portion of the muscle. Through serendipitous observation, the retracted edge of the undersurface of the muscle was retrieved to reveal the smooth undersurface of the pectoralis (**Fig. 5**). This observation spawned the hypothesis that the pectoralis muscle actually represents a laminated structure at the inferiormost level. When the inferior edge of the muscle is secured, one is traditionally only manipulating the superficial layer, while the deeper layer retracts superiorly. The significance of an incompletely controlled pectoralis muscle is addressed later.

Careful review of the pectoralis anatomy reveals an inferior origin from the fifth and sixth ribs.⁹ Cadaveric dissection into the substance of the muscle identified a deep layer coming off the fifth rib and a superficial layer from the sixth. Blunt dissection easily separates the layers, with the deeper plane representing approximately 30% of the muscle volume (**Fig. 6**). When the inferior border of the pectoralis is manipulated, only the superficial layer is being secured, unless the retracted deeper layer is deliberately retrieved and included with the superficial layer. The fifth wise man only appreciates the pectoralis major as a solid unit.

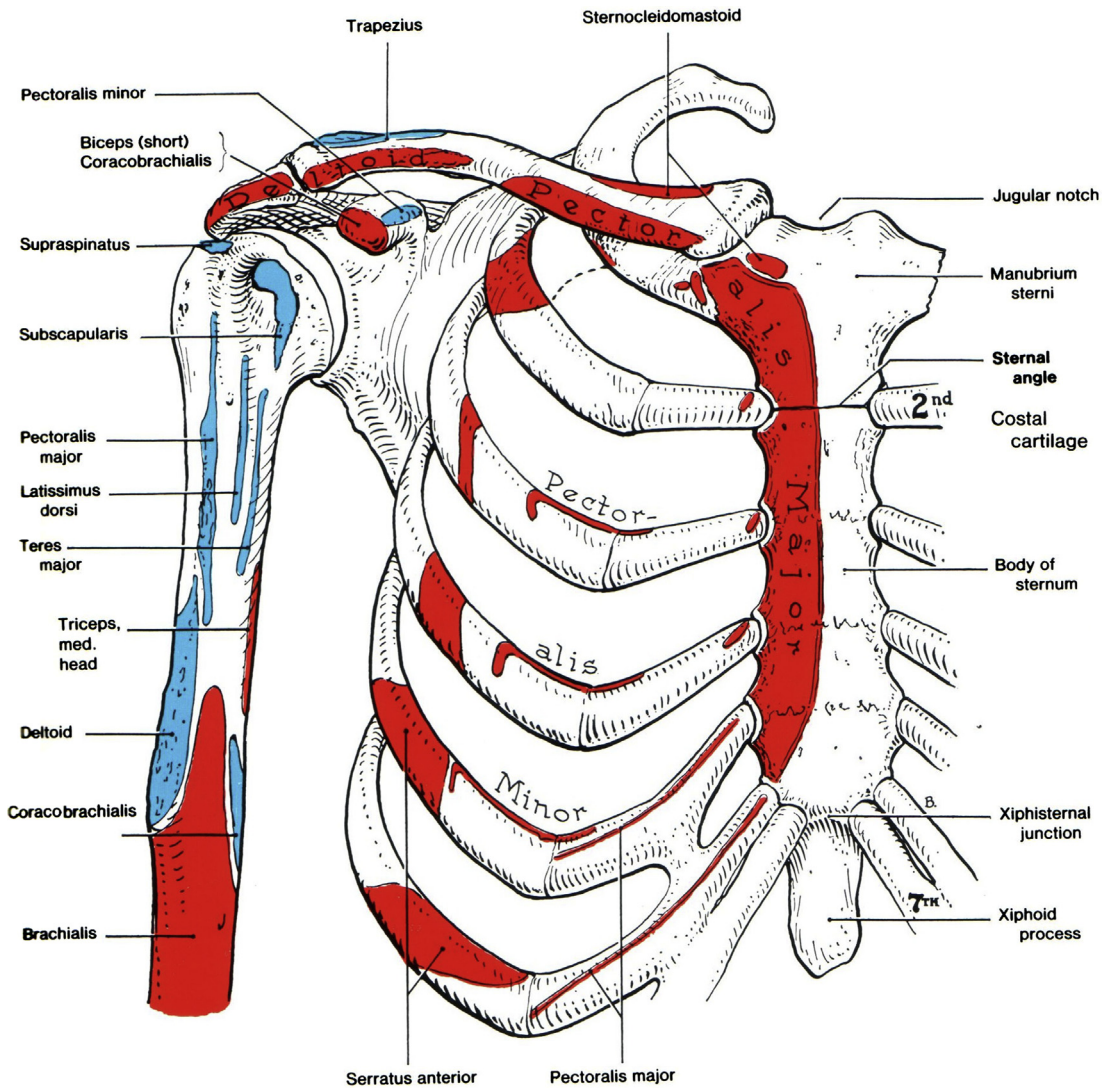


Fig. 4. Bones of the anterior chest wall showing the origin and insertion of pectoralis major. (From Moore KL, Agur AR, Dalley AF. Clinically oriented anatomy. Baltimore: Lippincott, Williams and Wilkins/Wolters Kluwer, 2013; with permission.)

Relationship to Inframammary Fold

Medial inflection point

The IMF is a critical landmark and essential feature of the aesthetically pleasing breast.¹ The exact limit of the IMF varies with the size of the breast and the size of the patient. The medial IMF and the lateral IMF may not be easily identified. In larger patients, the medial extent can seem to connect with the opposite breast and laterally may appear to go into the back. Most experienced surgeons have learned that manipulation of the breast is helpful to identify the medial and lateral extents of the IMF. The authors propose the terms medial inflection point (MIP) and lateral inflection point (LIP), as they more accurately represent the distal

ends of the IMF when the breast is folded in on itself (Fig. 7). The MIP and LIP likely represent external manifestations of the medial and lateral triangular fascial condensation⁶ (see Fig. 2). The MIP-LIP plane represents the base diameter of the breast footprint.¹⁴

The relationship of the IMF with the chest wall has been long sought and debated. It has been described to rest below the inferior pectoralis origin at the midaxial region of the breast.⁷ The exact relationship of the IMF with pectoralis has not been previously described. However, the relationship with the chest wall becomes relevant after mastectomy whereby the removal of the breast tissue separates the breast envelope from the

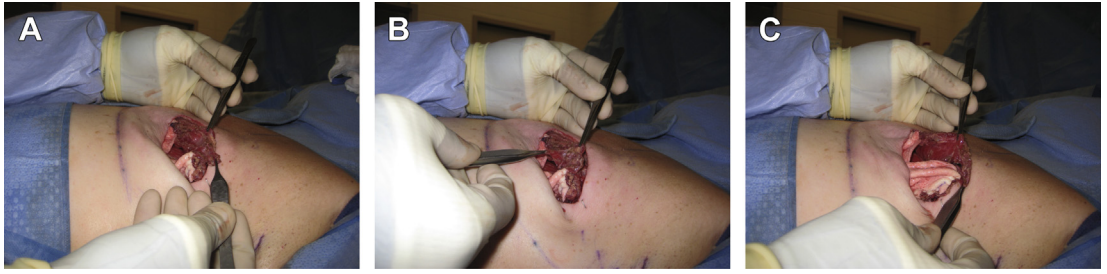

Fig. 5. Intraoperative view of the cut surface of the inferior border of the pectoralis major. (A) Superficial layer, (B) superficial and deep layer, and (C) deep layer with smooth undersurface.

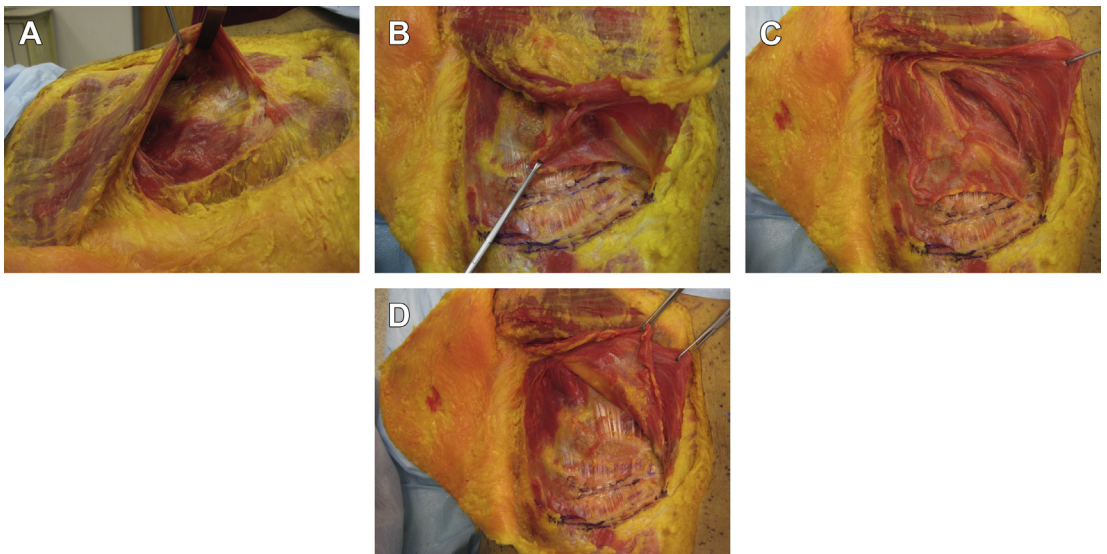


Fig. 6. Cadaver dissection of anterior chest wall. (A) Lateral approach to subpectoral space with origin from fourth, fifth, and sixth ribs, (B) separation of superficial and deep layers with rib origins marked, (C) deep layer bluntly separated and exposed, (D) deep layer retracted to reveal smooth undersurface of muscle.

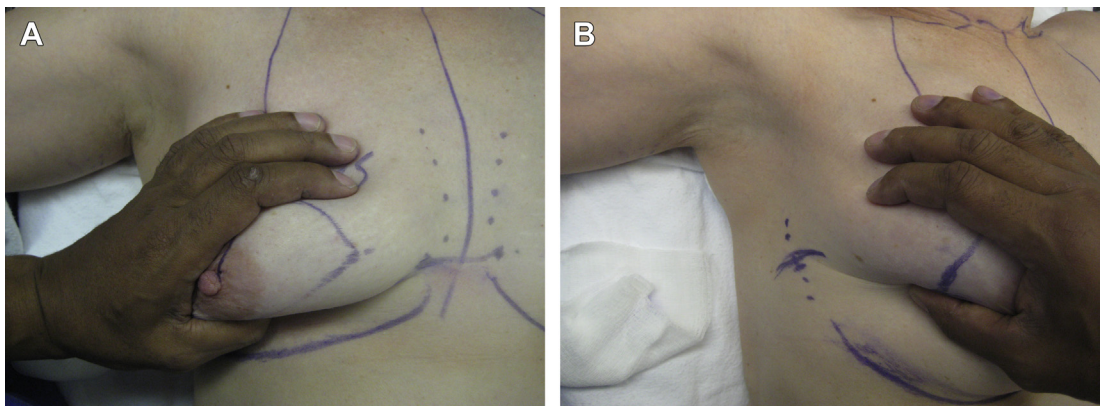


Fig. 7. Medial and lateral inflection points with folding of the breast. (A) MIP-medial and (B) LIP-lateral.

chest wall. Reestablishing this relationship is a priority in breast reconstruction. Various attempts to mark the natural position of the IMF with the chest wall have included sutures, staples, and dyes. The transcutaneous infiltration of methylene blue has been most useful in the authors' practice. It is here the relationship of the medial IMF with the pectoralis has unfolded. Routine use of this technique has demonstrated a consistent relationship of the MIP with the junction of the sternal and costal attachments of the pectoralis (**Fig. 8**). The value of this landmark is discussed in both aesthetic and reconstructive surgeries.

Lateral inflection point

The lateral extent of the IMF can be difficult to identify and can vary by the size of the breast and the size of the patient. However, the LIP can be identified in the same way as the MIP, by folding the breast on itself. It rests along the anterior axillary line but can seem to vary in larger patients. It is at the same level of the MIP and the 2 points form a horizontal plane with the nipple in patients without significant ptosis (**Fig. 9**). The plane of the MIP-LIP is not suggested as a reference point for ideal nipple position in individuals with ptosis at this time; however, it may represent a useful landmark in the future. Other than its location on the serratus anterior, no clinically significant reproducible internal anatomic relationship of the LIP and the chest wall could be identified. Skin attachments or zones of adherence of the lateral breast above the IMF have yet to be described. The lateral end of the triangular fascial condensation⁶ may be the structure responsible for the external LIP, but it is not easily identified intraoperatively.

Central inflection point

The central or midaxial portion of the IMF is simple enough to appreciate. It rests at the lowest part of the breast on the chest wall in line with the nipple. Yet its position can ride up onto the lower pole after breast augmentation or reduction. The authors

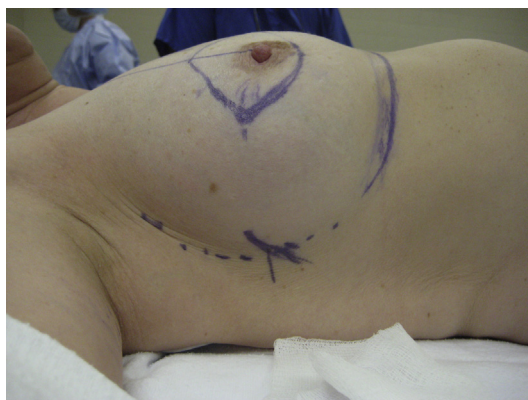

Fig. 9. Lateral inflection point on the anterior axillary line.

have chosen to define and designate this difference between the resting fold and the true fold anatomically (**Fig. 10**).¹⁵ When marking a patient for any breast procedure, surgeons mark the resting fold where the skin of the breast touches the skin of the abdomen, creating a natural crease. Under tension the true fold is revealed, which ultimately becomes the final fold after augmentation. The authors have used the term central inflection point (CIP) because a similar folding technique is used to identify it, like the MIP and LIP. The CIP rests on the true fold in line with the nipple on average 1.5 cm below the resting fold. The CIP likely represents the lower limit of the horizontal ligaments.⁶

The CIP, like the LIP, thus far has not been visualized to have an easily identifiable internal anatomic landmark. As previously discussed, the IMF is known to rest superficially at or below the level of the pectoralis origin. Therefore, the CIP also rests at, or below, the inferior pectoralis origin at the level of the sixth or seventh rib.² There is, however, a significant variability in how the IMF relates to the inferior pectoralis origin.⁸ In the authors' experience, internally the CIP has been visualized to lie approximately 5 cm below the MIP-LIP plane over the sixth rib.

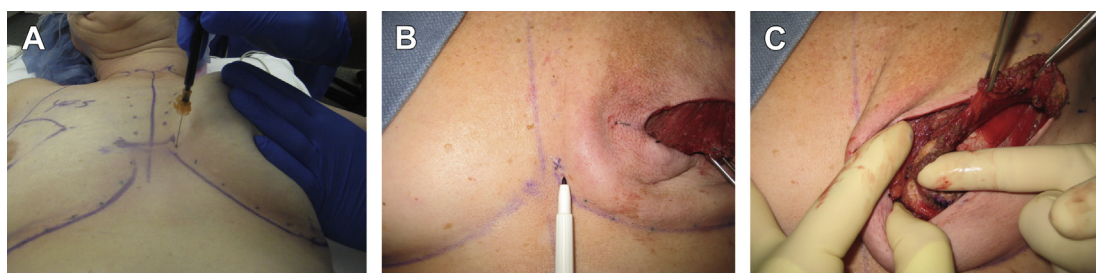

Fig. 8. Transcutaneous marking of the inframammary fold with methylene blue. (A) Intraoperative technique, (B) external MIP, and (C) internal MIP at the junction of the sternal and inferior origins of the pectoralis major.

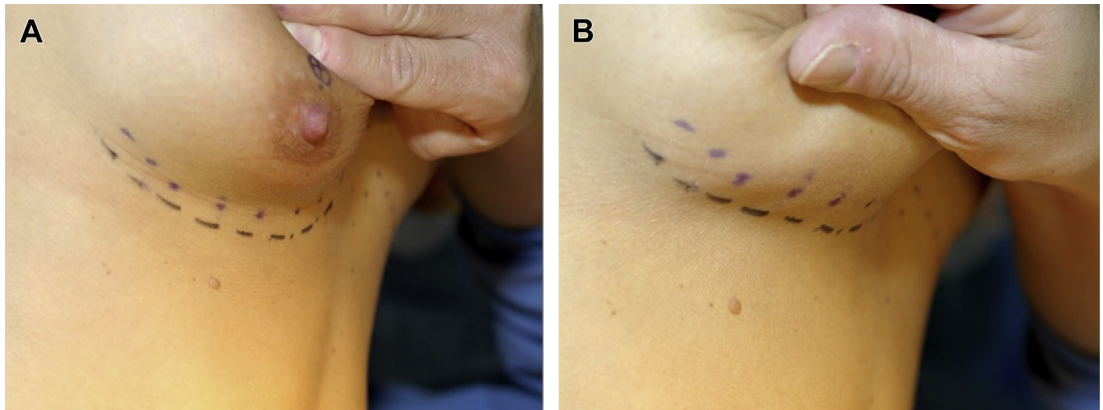


Fig. 10. Inframammary fold. (A) Resting fold; (B) true fold/central inflection point.

It is easy to see when one understands these anatomic boundaries how an incision may ride up onto the lower pole after breast reduction or augmentation with an IMF incision if the true fold is not taken into account. The final position of the breast, or the device, is the true fold. Most experienced surgeons have learned to appreciate the difference in the positions of the resting fold and the CIP on the true fold in breast surgery and incorporate it into their surgical planning.

In breast reconstruction, when superficial anatomy has been retained, reconstruction is straightforward. This CIP reference point is useful in immediate breast reconstruction where the anatomy has been poorly preserved, in delayed breast reconstruction where useful landmarks no longer exist, and in bilateral cases where a contralateral template is unavailable. The IMF can be successfully restored as an arc by marking a curvilinear line from MIP-CIP-LIP (**Fig. 11**).

CURRENT CONCEPT OF PECTORALIS ANATOMY AND ITS IMPLICATIONS *Right Angle Insertion of Inferior Origin to Vertical Sternal Origin*

The pectoralis major is manipulated not only for breast aesthetics but also for head and neck,

chest, breast, and upper extremity reconstructions. Yet it is almost universally perceived as having an L-shaped origin from the sternum and ribs (**Fig. 12**).¹⁶ This perception influences the surgeon's behavior when manipulating the muscle inferiorly for breast surgery, leading to stopping short and incompletely releasing the muscle medially. The accepted standard for breast augmentation is to limit release of the pectoralis off the sternal origin. The perception of an L-shaped inferior origin prompts most surgeons to stop short at its medialmost horizontal extent. The muscle, however, continues to curve obliquely along the cartilaginous portion of the sixth rib until it meets the sternum, which leaves 1 to 2 cm of unclaimed territory medially. This misconception is the perception of the sixth wise man.

Consequences with Augmentation

Lateral misidentification

The value of understanding the laminated nature of the pectoralis major muscle is an increased intraoperative appreciation of the anatomy. Once the muscle is understood to arise inferiorly from the fourth, fifth, and sixth ribs the muscular fibers encountered are better understood. Experienced

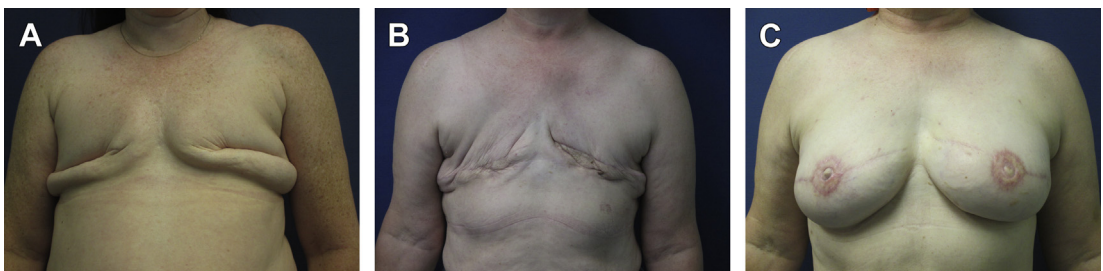

Fig. 11. Inframammary fold with delayed breast reconstruction. (A) Well-preserved IMF structure, (B) poorly preserved IMF, before (C) completed reconstruction with acellular dermis matrix and silicone implants, after.

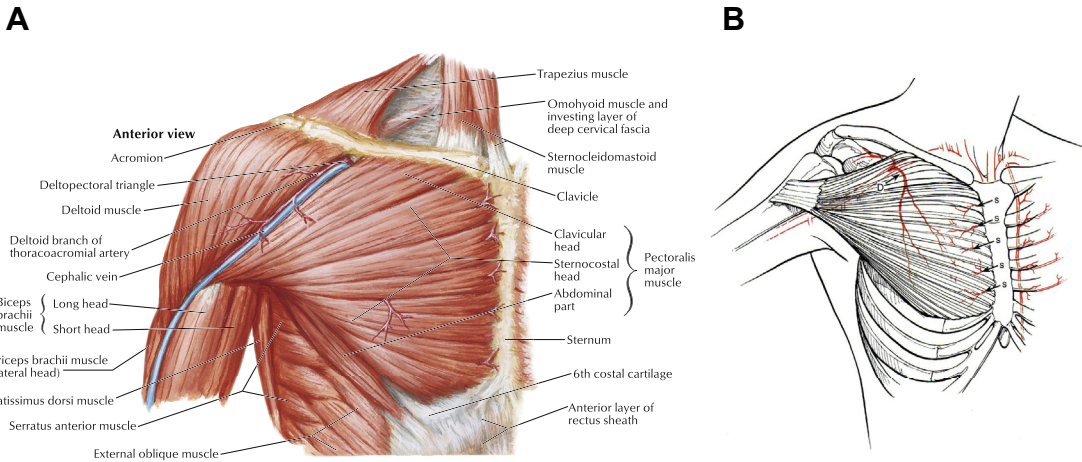


Fig. 12. Anterior chest wall demonstrating L-shaped inferior pectoralis origin. (A) Netter (Netter illustration from www.netterimages.com. © Elsevier Inc. All rights reserved) and (B) Mathes and Nahai. (From Mathes SJ, Nahai F. *Reconstructive surgery: principles, anatomy, and technique*. New York: Churchill Livingstone; 1997; with permission.)

surgeons have visualized the accessory fibers encountered with dissection in the submuscular plane.¹⁷

The lateral edge of the muscle is approached with the goal to access the avascular submuscular plane. Difficult access to this plane has been attributed to misidentification and dissection of the serratus.¹⁸ However, from typical access points (periareolar or central IMF), the serratus is located at least 5 cm laterally. The surgeon has likely found the dense interface in the pectoralis origin between the fifth and sixth ribs, which is not easily bluntly dissected (Fig. 13). Reorientation of dissection a few centimeters superiorly allows for entry into the correct plane. This maneuver is simply bringing the level of dissection above the fifth rib, where the avascular plane can be approached with ease. The sixth wise man

without an understanding of the laminated nature of the pectoralis believes he is disorientated and lost.

Underdissection

The subpectoral space is sufficiently developed to allow precise placement of the device. Internally, accessory fibers encountered medially are divided to develop the subpectoral space. Cadaveric dissection reveals that these internal accessory fibers arise from the fourth and fifth ribs and contribute to the deep layer of the pectoralis major. Release of these fibers does not completely separate the pectoralis from its inferior origin, with the remaining superficial layer from the sixth rib. With preservation of the superficial layer, the pocket remains completely submuscular. Disadvantages to complete submuscular device

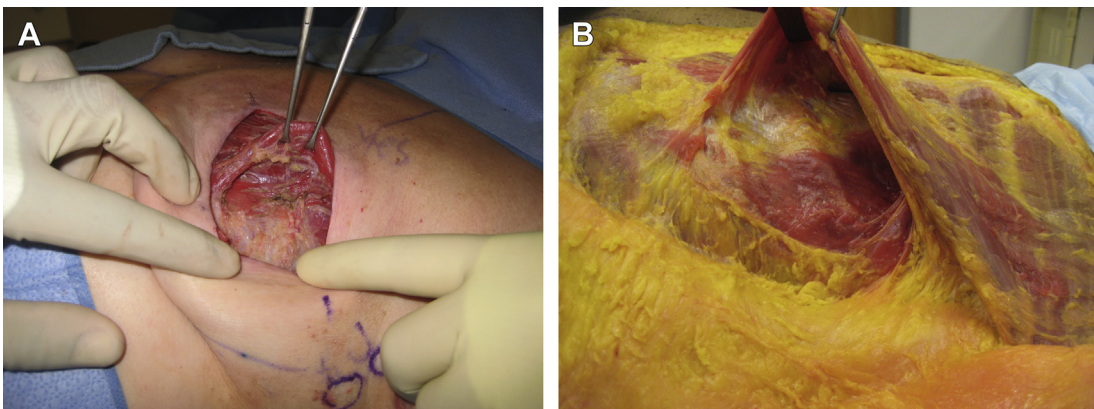


Fig. 13. Lateral border of pectoralis major at its inferior origin. (A) Intraoperative view of the fifth and sixth rib origin; (B) cadaveric view.

placement are prominent superior pole, tight lower pole, and potential snooty deformity.¹⁷

Division of the superficial layer inferiorly is the key step in partial subpectoral placement of the device. The medial fibers of the superficial layer are approached with caution as their significance is debated. Preservation of medial fibers is advocated to avoid disinsertion of sternal attachments. A more liberal release is encouraged to promote medial pole fullness. It is generally agreed to limit dissection off the sternum; however, where to stop is nebulous. It is here the significance of the MIP landmark becomes relevant. The MIP is the surface landmark where the superficial fibers from the costal surface of the sixth rib travel obliquely and join the horizontal fibers from the sternum. Once the MIP is reached, further dissection should be terminated.

Overdissection medially

Medial dissection superior to the MIP is tempting to allow larger implant placement. The consequence of overzealous dissection beyond the MIP is division of the pectoralis off the sternum.¹⁹ Division above the MIP can result in symmastia, window shading of the pectoralis, increased implant visibility, and traction rippling.¹³

Overdissection inferiorly

Inferiorly the superficial layer of the pectoralis major arises from the costal margin of the sixth rib and the aponeurosis of the external oblique muscle. Cadaveric and clinical dissection have shown the IMF to lie up to 2.0 cm below the inferior origin of the pectoralis.⁷ When the inferior border is approached from the subpectoral plane, the deep fibers from the fifth rib, previously referred to as accessory fibers, are divided first. Superficial fibers are next visualized and are divided for partial subpectoral placement. Division of the superficial fibers directly off the rib surface places the plane of dissection in close proximity to the IMF. Continuing dissection along this vector risks dissection under the IMF, with potential for migration of the implant and bottoming out as a late consequence. Appreciation of pectoralis anatomy with division of the superficial fibers above the rib margin aids in protecting the integrity of the IMF as a support structure. Division of the superficial layer at least 1 cm above the rib margin leaves a sufficient cuff of soft tissue to avoid retraction of muscular perforators and vector away from the horizontal ligaments of the IMF support structure.^{6,10}

The inframammary approach to breast augmentation potentially risks overdissection inferiorly. When the IMF is understood to be a support

structure, dissection down to the chest wall should be done with the intent of preserving as much of this structure as possible. Dissection from the inframammary incision toward the chest wall goes through part of the triangular fascial condensation.⁶ Directing the vector of dissection superiorly protects the horizontal ligaments, thus maintaining the support structure of the IMF. When a new IMF incision is required to achieve adequate lower pole projection, its position should not be below the CIP or no more than 1 cm below the resting fold.¹⁰ Below this level, dissection risks disruption of the horizontal ligaments and at minimum should be repaired to maintain its support mechanism.

Consequences with Implant-Based Reconstruction

Complete submuscular reconstruction

Cosmetic breast surgery and reconstructive breast surgery are frequently thought of as separate entities by the seventh wise man; however, both surgeries share the same goal: to provide an aesthetically pleasing breast. The reconstructive arena has special challenges because of alterations in the soft-tissue envelope and chest wall structure. Implant-based reconstruction can be especially challenging in getting the patient and the implant to cooperate with one another. Complete submuscular placement of the implant can provide an acceptable breast mound, but limitations in soft-tissue compliance can restrict ultimate shape and projection. Tight lower pole, blunted IMF angle, and superior displacement of the implant have fueled enthusiasm for the combination of acellular dermis matrix (ADM) with partial submuscular placement of the implant. This technique has allowed for improved and more consistent shape and projection of breast reconstruction.²⁰⁻²³ This approach is similar to partial submuscular breast augmentation with division of the pectoralis muscle off the chest wall inferiorly. The difference between the 2 is where the lower pole is supported with ADM in breast reconstruction and with breast soft tissue in augmentation.

Acellular dermis matrix-based reconstruction

Since the advent of acellular dermis-based reconstructions such as AlloDerm, the rate of reconstructions with ADM has increased nearly 25% during the past 5 years (**Fig. 14**) (data from LifeCell survey). The pectoralis major muscle is released inferiorly in a manner similar to dual-plane breast augmentation. Although the approach is internal (subpectoral) with augmentation and external with reconstruction, the goal is the same. Here the misconception of an L-shaped lower pectoralis border can be misleading.

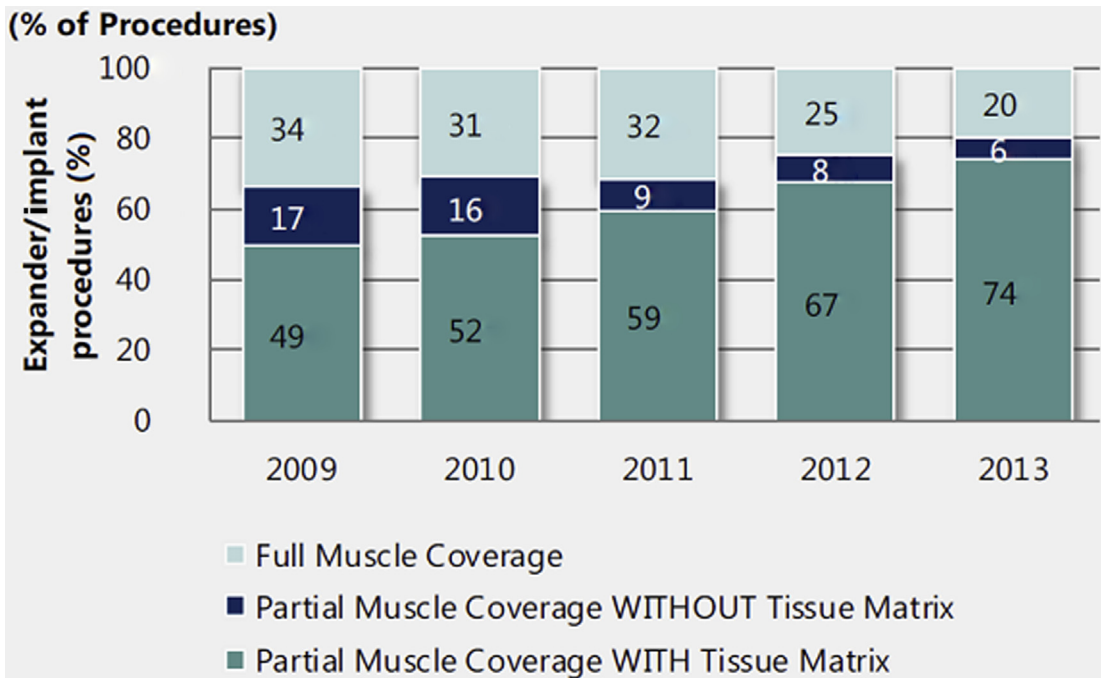


Fig. 14. Surgical technique used for tissue expander/implant procedures from 2009 to 2013.

With ADM-based reconstruction, the pectoralis is released up to its medial extent.^{20,21} The medial limit of the inferior pectoralis is confused with the L-shape frequently pictured.¹⁶ However, as shown with cadaveric dissection, inferiorly the superficial layer of the pectoralis continues obliquely along the sixth costal margin up to its sternal attachments at the MIP; this can be demonstrated with the surgical finger admitted to the medial limit of the pectoralis. When completely released up to the MIP, the finger is not restricted inferiorly and medial placement of the tissue expander is increased by 1 to 2 cm (Fig. 15). This procedure

avoids lateral implant placement and poor medial pole definition; this can take the appearance of an inverted dog ear medially. When fully appreciated, the pectoralis is released up to the MIP and the ADM is inset into the chest wall at this point.

The MIP, CIP, and LIP can be thought of as surface landmarks to the breast footprint described by Blondeel and Hijawi.¹⁴ The ADM is inset onto the chest wall at the MIP, continues in a curvilinear manner along the IMF to the CIP then up to the LIP. The LIP has been visualized to rest on the serratus anterior in line with the anterior axillary line. As previously mentioned, a specific corresponding

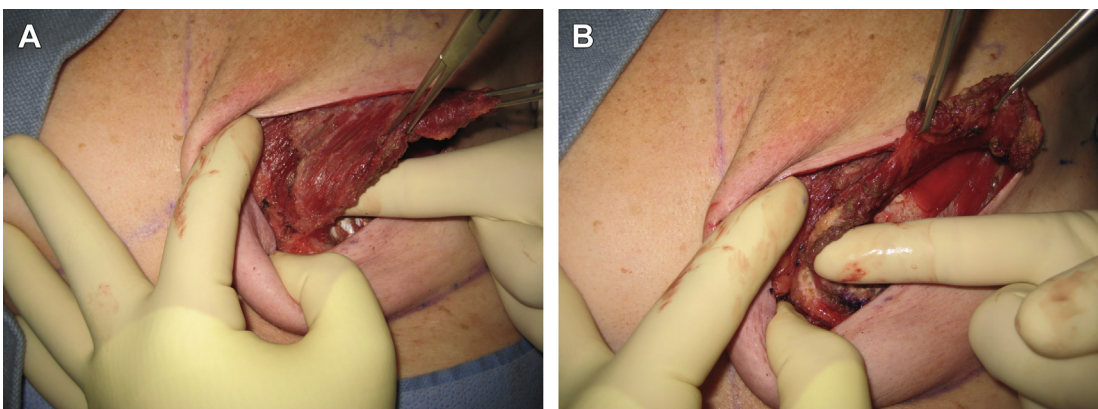


Fig. 15. Intraoperative approach to the MIP following release of the pectoralis inferiorly. (A) Incomplete release with inferior descent of the surgical finger restricted; (B) full release up to the MIP.

internal landmark for the LIP has yet to be identified, but it can be located. The LIP lies on a horizontal plane with the MIP along the anterior axillary line. With breast reconstruction, it is best matched with base diameter of the selected tissue expander. The base diameter is a function of chest wall anatomy, not size of breast or weight of the patient. For example, for a tissue expander with a 14 cm base diameter, the LIP is marked 14 cm lateral to the MIP. The marked LIP should not extend past the anterior axillary line; this allows for a customized pocket for the selected device, for the desired hand-in-glove fit.

Failure to resecure the deep layer Following inset of acellular dermis along the IMF from MIP to LIP, a precise submuscular pocket has been created. Surgery is completed with enclosure of the tissue expander under the newly created pectoralis/acellular dermis pocket. The inferior border of the pectoralis is approximated to the superior border of the ADM. As previously described, the pectoralis is a laminated structure with both a superficial and a deep layer. Typically, the free edge of the pectoralis is grasped; however, this represents only the superficial layer. The deeper layer has retracted superiorly, and unless deliberately retrieved is not secured with the superficial layer (see Fig. 5).

The significance of an uncontrolled deep layer is difficult to appreciate without first understanding its existence and its volume. It represents approximately 30% to 50% of the muscle volume and when not under sufficient tension atrophies, thus

reducing the volume of tissue for upper pole coverage. The pendulum has swung from excess upper pole volume with total submuscular coverage to deficient upper pole with the increasing popularity of ADM in breast reconstruction. An aesthetically pleasing breast has an upper pole to lower pole ratio of 45:55, with a slope that is linear or slightly concave.²⁴ Multiple techniques are available to augment upper pole volume with shaped breast implants, intracapsular ADM,²² and fat grafting.^{15,23} The authors propose that the simplest and cheapest technique is to retrieve the deeper layer from the fifth rib and secure it with the superficial layer (Fig. 16); this can be appreciated when the undersurface of the muscle takes on a smooth appearance after the deep layer is retrieved and maintains tension and prevents partial muscle atrophy.

An additional consequence of an unsecured deep layer is a thin muscle junction with ADM; this increases the risk of delayed implant exposure at the muscle/ADM junction following inflation of the tissue expander. After separation of this thin junction, the expander rests directly under thin mastectomy flaps. If the junction is near the incision line, exposure of the expander may be imminent (Fig. 17). The risks are particularly magnified in patients requiring postoperative radiation. The need for secondary procedures such as latissimus flap coverage, although not completely eliminated, has been significantly reduced in the authors' practice, and their experience with this simple adaptation has been most favorable with no increase in operative time, expense, or risk.

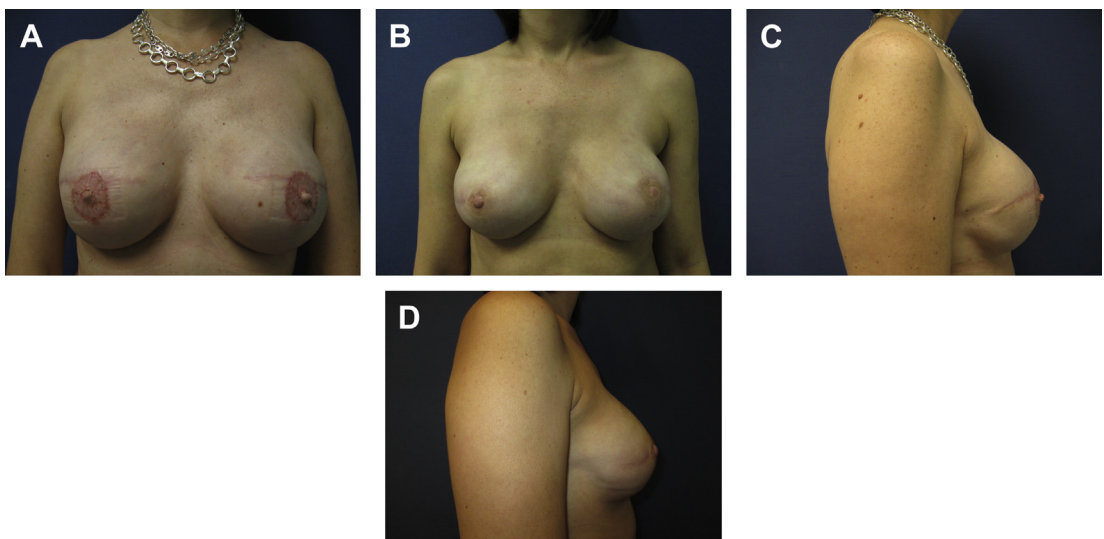


Fig. 16. Final breast reconstruction outcome with ADM and high-profile silicone implants. (A, C) Reconstruction with superficial layer control of the pectoralis with poor upper pole volume and slope; (B, D) reconstruction with dual-layer control of the pectoralis with improved upper pole volume and slope.

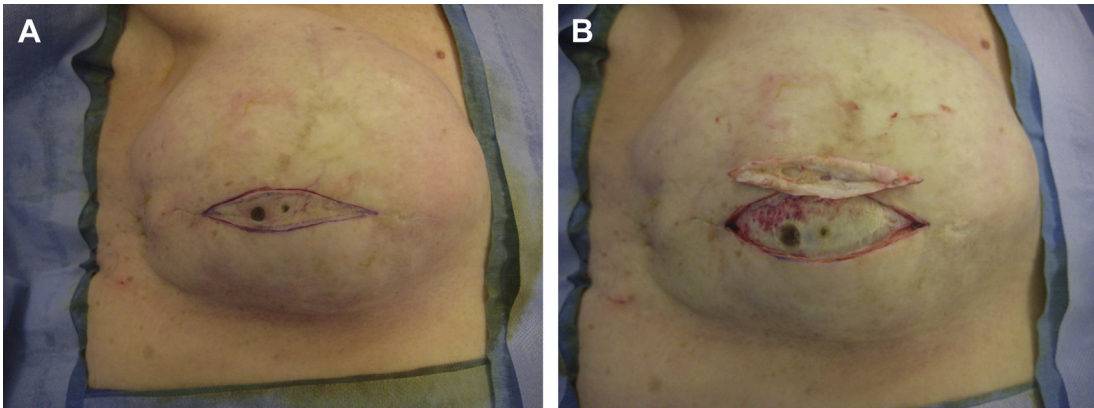


Fig. 17. Threatened exposure of tissue expander at incision line occurring at the junction of pectoralis and ADM. (A) Exposure through scar, (B) Exposure at pectoralis/AlloDerm junction.

Clinical Applications to Mastopexy and Reduction

Mastopexy and breast reduction techniques seek to reduce the skin envelope and reshape the breast conus for improved shape, size, and projection of the breast.¹⁵ Although there is significant debate regarding the specific technique, there is less controversy than implant-based surgery. In both procedures, the skin envelope is reduced to match the final size of the breast conus. The IMF is marked for operative planning, regardless of the specific technique chosen. In smaller patients and with smaller breasts, markings are straightforward. However, in larger patients or breasts, the distal ends of the IMF can be difficult to pinpoint. It is here the value of the MIP, LIP, and CIP can be appreciated as reproducible external landmarks.

The medial end of the IMF when marked too short may result in a dog ear and in very large reductions risk crossing the midline. The MIP is a useful reference point to terminate the surgical incision. Similarly, the lateral end of the IMF may result in a dog ear if marked too short. A particular challenge in patients with BMI greater than 35 is where to stop with the lateral incision as it blends with the patient's lateral axillary lipodystrophy. As the LIP terminates at the anterior axillary line, the lateral incision should be limited to this point (**Fig. 18**). The additional challenge of achieving symmetry with bilateral surgery can be reduced with availability of reproducible landmarks.

Scars are an unavoidable consequence to any surgery. Plastic surgeons strive to minimize scar appearance by placing the scar in a favorable location. A most frustrating element to breast surgery is the mobility of IMF scars and their tendency to ride up. With breast augmentation, the CIP is identified and the incision is preemptively placed

on the true fold in anticipation of a final acceptable position of the scar. The tension created by the implant exposes the true fold, which ultimately becomes the final fold. The same mechanism is at play after mastopexy/reduction. When closed under excessive tension, the pressure of the conus on the skin envelope exposes the true fold, which ultimately becomes the final fold. Thus, the incision appears to ride up. Adequate preoperative planning for a sufficient skin envelope should balance with judicious reduction of the breast such that tension on the lower IMF is minimized. The CIP when marked during mastopexy/reduction can serve as a useful tension meter.

DISCUSSION

All surgeons equally desire to avoid unintended outcomes. The reasons for unintended outcomes are multifactorial and can be due to patient selection, technique, and experience. The surgeon never expects to be the direct cause. Yet something as simple as a narrow perspective has been made by many learned men. The anatomy of the breast from the skin envelope, breast tissue, underlying musculature, and chest wall are all intimately related. Regardless of the various techniques for cosmetic, functional, and reconstructive breast surgery, the goals and principals are the same.

Appreciating the dynamic nature of the breast and these new insights into muscle and breast anatomy allows the plastic surgeon to also appreciate the surface structure and how it relates to the IMF and the chest wall and their clinical implications. Folding the breast on itself reveals the MIP, CIP, and LIP along the IMF. These are valuable reproducible surface landmarks, which have both useful internal and external significance in augmentation, mastopexy, reduction, and reconstruction.

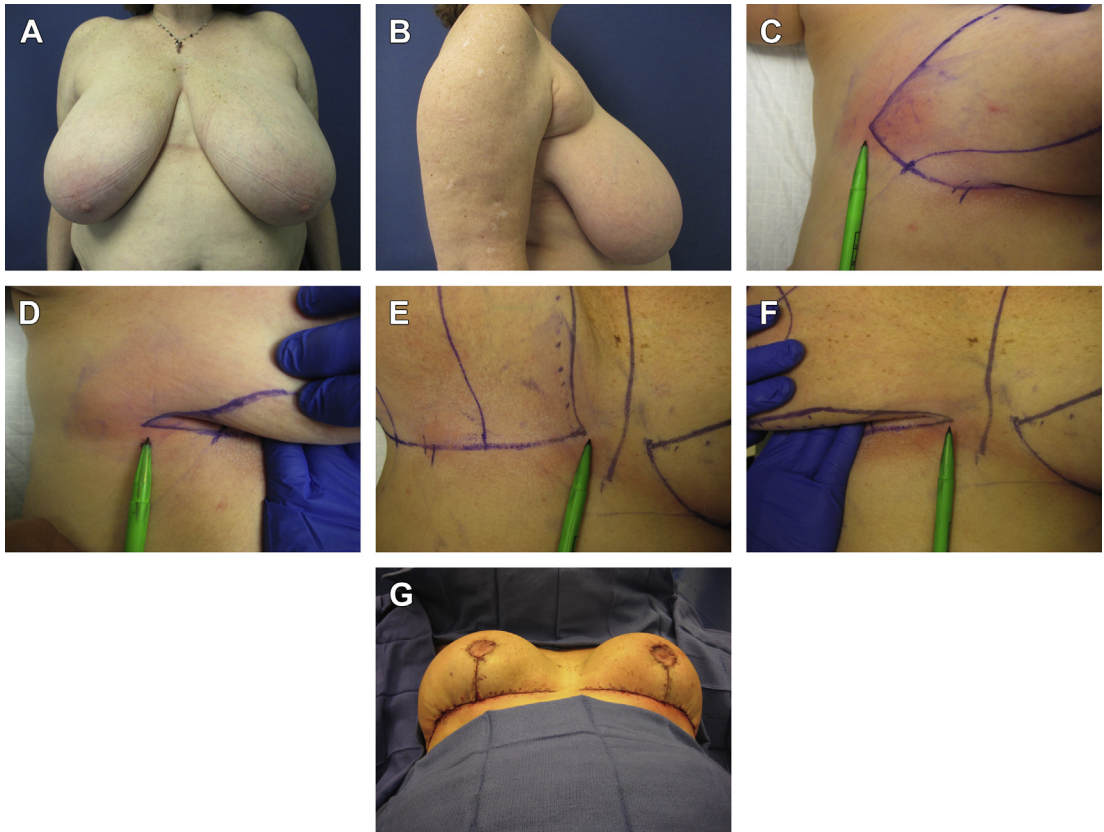


Fig. 18. Breast reduction of 1300 g in a patient with body mass index 35 kg/m². (A, B) Preoperative images. (C, D) LIP at rest and with folding; (E, F) MIP at rest and with folding. (G) Intraoperative image.

Further appreciation of the dynamic nature of the pectoralis has been heretofore underappreciated. It is well known that the pectoralis major is a type V flap and can be split segmentally when based off its medial perforators.²⁵ Less well known is the laminated nature of the pectoralis muscle with a superficial layer and a deep layer, arising from the fifth rib and sixth rib, respectively. Most experienced surgeons have visualized portions of this layered muscle in some manner and from various approaches but never understood its full and true nature. With pure submuscular augmentation, often the deep layer only is separated, whereas both layers are divided with dual-plane augmentation techniques. In ADM-based breast reconstruction, only the superficial layer heretofore has been secured to the ADM. A dual-layer closure is recommended to fully control the pectoralis to maintain muscle tension, upper pole volume, and enhanced coverage of the device.

The authors have tied multiple observations and practices, much like observations of the learned men of Indostan, into a more comprehensive animal. Understanding in one area will lead to greater understanding in another and to improved outcomes.

Editorial Comments by Bradley P. Bengtson, MD

The laminar anatomy of the pectoralis major muscle, the reflection points of the breast and the inframammary fold are anatomic structures we look at every single day, but do not really understand. The specific muscle and fascial anatomy, vectors, insertions and variability significantly affect outcomes in breast augmentation, revision and reconstruction. The muscles are not single uniform sheets of muscle but laminar in nature. If these individual layers are not taken into account and are overly released surgeons can create window-shading and minimize muscle coverage. If under-released they can create an implant position is too far lateral and/or too high. The fascial fiber of the lower portion of the breast insert at an oblique angle and the true fold of the breast is actually 1.5–2.0 cm lower than the resting fold or inferior skin reflection point. This true fold is where the base of the implant will rest unless the fold is otherwise sutured or set higher and is a common reason for fold malposition. These nuances in patient anatomy are vitally important for the plastic surgeon to understand and obtain consistent long-term results.

REFERENCES

1. Carlson GW, Grossl N. Preservation of the inframammary fold: what are we leaving behind? *Plast Reconstr Surg* 1996;98(3):447–50.
2. Muntan CD, Sundine MJ. Inframammary fold: a histologic reappraisal. *Plast Reconstr Surg* 2000;105(2):549–56 [discussion: 557].
3. Boutros S, Kattash M. The intradermal anatomy of the inframammary fold. *Plast Reconstr Surg* 1998;102(4):1030–3.
4. Maillard GF, Garey LJ. An improved technique for immediate retropectoral reconstruction after subcutaneous mastectomy. *Plast Reconstr Surg* 1987;80(3):396–408.
5. Bayati S, Seckel BR. Inframammary crease ligament. *Plast Reconstr Surg* 1995;95(3):501–8.
6. Matousek SA, Corlett RJ. Understanding the fascial supporting network of the breast: key ligamentous structures in breast augmentation and a proposed system of nomenclature. *Plast Reconstr Surg* 2014;133(2):273–81.
7. Nanigian BR, Wong GB. Inframammary crease: positional relationship to the pectoralis major muscle origin. *Aesthet Surg J* 2007;27(5):509–12.
8. Madsen RJ Jr, Chim J. Variance in the origin of the pectoralis major muscle: implications for implant-based breast reconstruction. *Ann Plast Surg* 2015;74(1):111–3.
9. Moore KL. Clinically oriented anatomy. 2nd edition. Baltimore (MD): Williams & Wilkens; 1985.
10. Tebbetts JB. Dual plane breast augmentation: optimizing implant-soft-tissue relationships in a wide range of breast types. *Plast Reconstr Surg* 2001;107(5):1255–72.
11. Spear SL, Parikh PM. Acellular dermis-assisted breast reconstruction. *Aesthetic Plast Surg* 2008;32(3):418–25.
12. Pacik PT. Augmentation mammoplasty: enhancing inferomedial cleavage. *Aesthet Surg J* 2005;25(4):359–64.
13. Lindsey JT. The case against medial pectoral releases: a retrospective review of 315 primary breast augmentation patients. *Ann Plast Surg* 2004;52(3):253–6 [discussion: 257].
14. Blondeel PN, Hijawi J. Shaping the breast in aesthetic and reconstructive breast surgery: an easy three-step principle. *Plast Reconstr Surg* 2009;123(2):455–62.
15. Bengtson B. Acellular dermal matrices in secondary aesthetic breast surgery: indications, techniques, and outcomes. *Plast Reconstr Surg* 2012;130(5 Suppl 2):142S–56S.
16. Mathes SJ, Nahai F. Reconstructive surgery: principles, anatomy and technique. Baltimore (MD): Churchill Livingstone; 1997.
17. Hammond DC. Atlas of aesthetic breast surgery. Edinburgh (United Kingdom): Saunders; 2008.
18. Khan UD. Muscle-splitting breast augmentation: a new pocket in a different plane. *Aesthetic Plast Surg* 2007;31(5):553–8.
19. Sanchez ER, Howland N. Anatomy of the sternal origin of the pectoralis major: implications for subpectoral augmentation. *Aesthet Surg J* 2014;34(8):1179–84.
20. Breuing KH, Warren SM. Immediate bilateral breast reconstruction with implants and inferolateral AlloDerm slings. *Ann Plast Surg* 2005;55(3):232–9.
21. Breuing KH, Colwell AS. Inferolateral AlloDerm hammock for implant coverage in breast reconstruction. *Ann Plast Surg* 2007;59(3):250–5.
22. Maxwell GP, Gabriel A. Revisionary breast surgery with acellular dermal matrices. *Aesthet Surg J* 2011;31(6):700–10.
23. Spear SL, Sher SR. Focus on technique: supporting the soft-tissue envelope in breast reconstruction. *Plast Reconstr Surg* 2012;130(5 Suppl 2):89S–94S.
24. Mallucci P, Branford OA. Concepts in aesthetic breast dimensions: analysis of the ideal breast. *J Plast Reconstr Aesthet Surg* 2012;65(1):8–16.
25. Tobin GR. Pectoralis major segmental anatomy and segmentally split pectoralis major flaps. *Plast Reconstr Surg* 1985;75(6):814–24.